

RESTORATIVE
Effective Cavity Liner
Randy S. Weiner, DMD, pg. 136

TWO PEER-REVIEWED CE CREDITS
Management of Plaque-Related Soft-Tissue Trauma
Ahmad Soolari, DMD, MS, et al pg. 96

BUYERS' GUIDE
Fiber Posts and Pins,
pg. 138

JULY 2013

DENTISTRY TODAY

DENTISTRYTODAY.COM

VOLUME 32 NO. 7

THE NATION'S LEADING CLINICAL NEWS MAGAZINE FOR DENTISTS

JULY 2013

AESTHETICS



Ross W. Nash, DDS
pg. 114

TECHNOLOGY



Stephen Abrams, DDS
pg. 104

AESTHETICS



Peter Harnois, DDS
pg. 120

ENDODONTICS



Jack S. Roth, DDS
pg. 108

Readers' Choice

27th
Annual

TOP

1000 PRODUCTS

Special section begins on page 41

TOP 100 PRODUCTS

A New Perspective on Minimally Invasive Veneer Techniques



Peter Harnois,
DDS

Full-prep veneers remain the standard in our dental education, if not our practices. Not until the last decade have thin veneer techniques been introduced to students as an appropriate treatment methodology, when indicated.

Today, our patients' increasing dental IQ is driving their demand for a less invasive approach to aesthetic treatment. This article will present a case report demonstrating the latest generation of thin veneers (Lumineers [DenMat]). This clinical treatment approach represents the opportunity for responsible aesthetics, while always assessing the requirement for the removal of healthy tooth structure. DenMat's new approach and educational platform for Lumineers, called Thinnovation, is not just about no-preparation dentistry, though we must always consider the concept of choosing the best possible approach for each patient, based on individual needs and circumstances.

CASE REPORT

Diagnosis and Treatment Planning

A 28-year-old female patient, Ashley, presented to our office. She had completed 3 years of orthognathic treatment with her oral maxillofacial surgeon and her orthodontist. She specifically sought a dentist who offered no-prep style veneers. Her chief complaint was her smile or, in her words, the lack of "showing teeth" when smiling. In addition, she did not like the quality of the teeth/smile that did show (Before Image and Figure 1).

The patient presented with a postorthodontic removable upper Essix-style retainer, and with healthy periodontium and stable occlusion, showing no temporomandibular

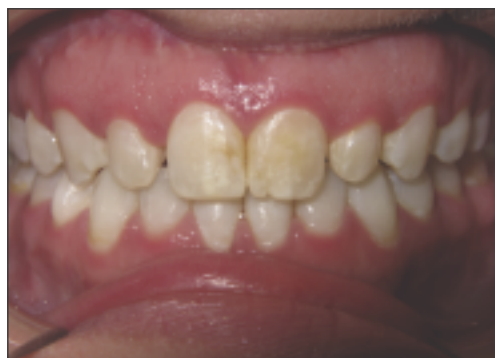

Figure 1. Pre-op smile retracted, frontal view.




BEFORE

Before Image. Pre-op smile retracted, frontal view.

joint disorder (TMD) symptoms or bruxing/clenching. Full dental records were performed and a LUMISmile (DenMat) picture taken to produce a digital smile makeover. Her principal aesthetic issues included multiple diastemas, peg lateral incisors, and hyperplastic gingival tissues that covered the gingival one third of the maxillary (peg) lateral incisors (teeth Nos. 7 and 10). Also evident was stained, mottled, and hypocalcified enamel on all upper teeth.

At her initial appointment, it was apparent that she had already done her homework. She had requested information from her oral surgeon about the current landscape of porcelain veneer options and already knew about thin veneers, specifically Lumineers. She had followed up by visiting DenMat's patient Web site (lumineers.com) to learn more about what was possible with minimal-prep veneer systems. She already knew what she wanted. This experience is increasingly common. As a general dentist practicing aesthetic dentistry for the past 31 years, I have found that the majority of new patients have some idea of what they seek clinically. Today's patients are more empowered with the knowledge available to them and often have gone beyond what they've seen on television or heard from friends to visit Web sites and



AFTER

After Image. The final smile.

educate themselves. Our role is to help them determine appropriate treatment options and to outline the probable outcome based on the current state of their dentition. Giving patients all possible options, and then letting them decide, has proven to be a consistently successful beginning to case acceptance.

Ashley's first appointment was more focused on how her new smile could look, in terms of shapes and shades, than it was talking about the difference between minimal- or no-prep veneers (such as Lumineers) and traditionally prepped veneers. She knew that she wanted an aesthetic solution that minimized the removal of her tooth structure. One of her first comments to me was, "I don't have that much tooth structure as it is, so I don't want my teeth made any smaller!"

As part of the aesthetic consult, LUMISmile photos were taken to provide a digital smile makeover in less than 30 minutes. (The SNAP Digital Imaging system is another useful diagnostic tool that could be used here.) A comprehensive smile analysis was conducted, including completion of a Smile Analysis Form by the patient. From this information, the patient communicated that she did not like to smile due to her small, misshapen, and discolored teeth. After completing a full

continued on page 124

A New Perspective on Minimally...

continued from page 120

dental exam, smile analysis, and oral cancer screening (which included the use of the VELscopeVx [DenMat]), we presented the patient with her LUMISmile before and after digital images (Figures 2a and 2b).

Our patients' responses at this stage are often emotional, and this patient was no different. The case proposal for 8 Lumineers for teeth Nos. 5 to 12, with a post-treatment removable retainer/nightguard, was accepted.

Clinical Protocol

Treatment started in early December 2012, with a prophylaxis. A one-hour chairside whitening was done (Lumibrite and Sapphire light [Both by DenMat]), followed by one week of home whitening using a 35% carbamide peroxide gel (Lumibrite) with custom trays (30 minutes per day for one week was prescribed, and followed). Our patient's teeth were whitened from 2M1 to OM3/OM2, and the porcelain shade the patient selected was OM2. (Note: Clinicians can use any effective whitening system and technique of their choosing. For example, with the EPIC laser technique [BIOLASE Technology], treatments can be performed in as little as 30 minutes.) Possible laser gingivoplasty was also discussed with the patient at this time, though she expressed hesitation with the procedure so a final decision was postponed.

One week after whitening and shade selection, enamel-contouring procedures were begun. Enamel contouring has long been considered a somewhat gray area in achieving the desired outcome sought by a patient. The problem has been that traditional prep is well defined, but enamel contouring is not. There are no set principles of smile design. Beauty is in the eye of the beholder, and there is no right or wrong. The new Thinovation approach is based on the principles of smile design and utilizes minimally invasive concepts of tooth preparation to achieve the desired result. For the first time, the Thinovation concepts of enamel contouring strive to define the proper principles of contouring to achieve the aesthetic, natural lifelike result that the patient seeks from the doctor.

Initially, it is our job to obtain the necessary information from the patient. We need to listen and photo document each person's individual pre-op situation. LUMISmile allows the practitioner to show each patient an individual digi-



Figure 2a. Before. Patient's before image, which is sent to DenMat digitally.




Figure 2b. After. Patient's LUMISmile (DenMat) digital after, received in the same consult appointment from DenMat to give the patient an idea of her eventual result.

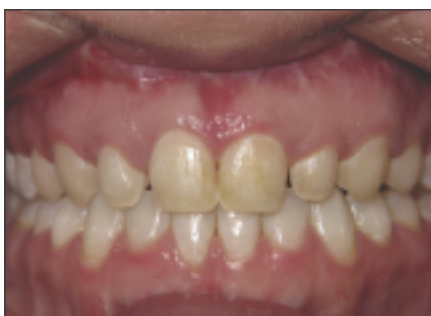

Figure 3. Frontal retracted contoured/prelaser.

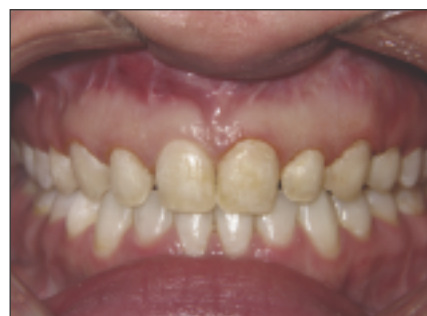

Figure 4. Immediate postlaser.

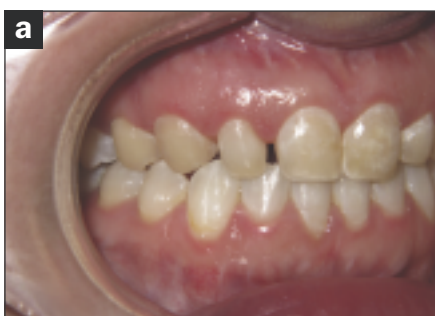

Figure 5a. Right lateral, postlaser after one week of healing.

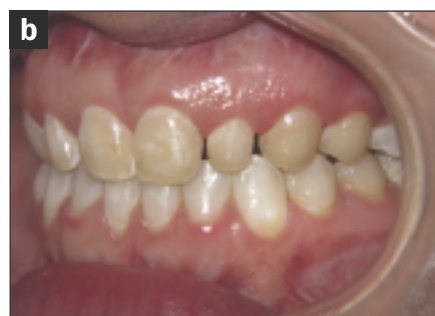

Figure 5b. Left lateral, postlaser at one week.

tal smile makeover and is a tremendously successful visual starting point for discussing with the patient what is possible. In more advanced cases, live models, intraoral mock-ups, and approved provisionals are tremendous diagnostic tools that Thinovation allows a doctor to employ. In this patient's case, enamel contouring was not only what she sought from this dentist's office, but a viable option for treatment utilizing the following Thinovation concepts of enamel contouring: correct size discrepancies, adjust occlusal plane cants, adjust midline cants, adjust suprabulges and incisal bevel.

Understanding smile design concepts will dictate what to contour. Any imperfection is magnified if not con-

toured. In Ashley's case, there were certain bulges and line angles that, if not properly contoured, would have looked thick, bulky, and unnatural in the end result. Her natural teeth had a facial bulge to them that needed to be reduced to elongate her teeth and close the diastemas and achieve the natural look she wanted. A very important concept for the doctor to grasp is that Lumineers is an additive cosmetic procedure. Properly informing the patient that smoothing the "bumps" off of her teeth to achieve a natural result made perfect sense to her. The fact that I could also inform her that enamel contouring would not induce any biological harm to her teeth made her feel even better about the prescribed treatment.

After she signed the informed consent form, we focused on 3 clinical objectives. First, an incisal bevel would be created to allow for design of the patient's veneers with proper form and function with her existing occlusion. The heights of contour on the facial aspect would be reduced so all teeth would slope in toward the incisal aspect from the facial height of contour. Finally, all the line angles would be reduced and rounded, and facial embrasures would be deepened where there was interproximal contact of teeth to allow for well-defined line angles and a natural depth of field to the facial embrasures. All of this was accomplished without any patient discomfort, local anesthetic, or temporization.

As mentioned, the patient was initially reluctant to trim tissue with laser, so we contoured her enamel first and then showed her what a difference it would make if we could expose the natural tooth structure still under her hyperplastic tissue. Also, I wanted to perform an aesthetic crown lengthening (in general), since the patient showed her attached gingiva when she smiled. Once she saw and understood that, we performed the laser gingivoplasty using a diode laser (SOL Diode Laser [DenMat]) at one W continuous wave setting, uncovering the remaining clinical crown of teeth Nos. 5 to 12. (Note: There are numerous other dental diode lasers suitable for this procedure such as Picasso Lite [AMD LASERS], EPIC 10 [BIOLASE Technology], SIRO-Laser Advance [Sirona Dental Systems] Odyssey Navigator [Ivoclar Vivadent], and so on.) This created a more natural result and a more symmetrical gingival display in general (Figures 3 and 4). We let healing occur over one week (Figures 5a and 5b). Final impressions were then taken along with records and photos.

In preparation for Lumineers placement, 2 full-arch impressions were taken using a vinyl polysiloxane (VPS) impression material (Splash! [DenMat]). In addition, a face-bow (Panadent), stick-bite, and a closed-tray bite registration were also taken. Then, all was sent to DenMat's full-service dental lab in California. In addition, 8 post-contouring photos were taken and submitted through an online Web portal. An Essix .040 thickness removable retainer was fabricated for the patient to wear full-time until the placement of her veneers.

Once the laboratory team received the materials from our office, the impressions were scanned to produce digital models for fabrication of the first set of digital designs. Three days later, digi-

Digital design was used, as well as pretreatment patient imaging, which supports predictable results.

tally designed previews were e-mailed to me for review. After the design previews were altered, per my instructions, an approved set of previews (Figures 6 to 10) were sent for final fabrication of the veneers. These approved digital previews were made possible by implementing the previously discussed smile design concepts and proper enamel contouring to achieve the desired lifelike aesthetic result the patient was seeking. The completed Lumineers were sent 13 days later.

Placement Appointment

Lumineers were placed following the steps in "The Doctor's Guide to Lumineer Placement." The lab-etched Lumineers were treated with porcelain conditioner and prime. The teeth were then polished with porcelain laminate polishing paste found in the Lumineers Placement Kit (DenMat). Using Ultra-Bond (DenMat) try-in paste, I placed teeth Nos. 7 and 8 with the supreme white shade and teeth Nos. 9 and 10 with shade B-O. Our patient selected the supreme white shade for her OM2 Cerinate veneers placement.

Her teeth were polished again with porcelain laminate polishing paste. The arch was isolated with Sapphire whitening system cheek retractors and isolated (Paint-On Dam [DenMat] placed on lingual aspect of teeth Nos. 4 to 13).

Teeth Nos. 5 to 12 were etched with 30% phosphoric acid, rinsed, and dried. Five coats of Tenure A and B (DenMat) self-cure adhesive were applied to the teeth and dried. Next, one coat of Tenure S was applied to both teeth and to the Lumineers, then thinned with air.

The Lumineers were loaded and placed in sequence of teeth Nos. 8 and 9 using a Lumigrip and supreme white UltraBond. After wiping off excess cement, teeth Nos. 7 and 10 were placed. Using a 2-mm tack-curing tip attached to a Sapphire curing light, teeth Nos. 8 and 9 were spot-cured for one second. Teeth Nos. 6 and 11 were then placed. Teeth Nos. 7 and 10 were then tack-cured for one second. Teeth Nos. 5 and 12 were placed. Teeth Nos. 5, 6, 11, and 12 were tack-cured for one second and remaining material was wiped off with brushes dipped in Tenure S. Final curing of 5 sec-

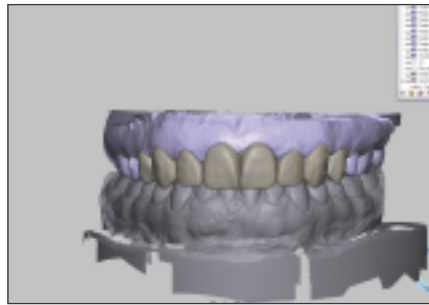


Figure 6. Frontal view (solid).

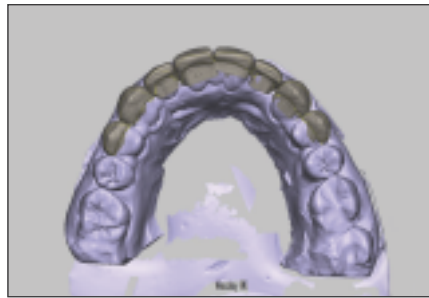


Figure 9. Occlusal view (solid).

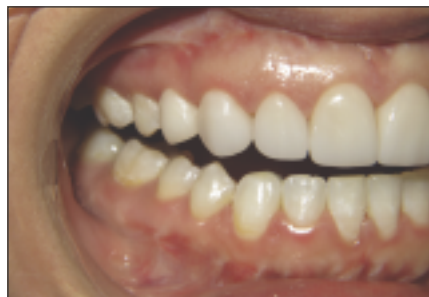

Figure 12. Right lateral view retracted.

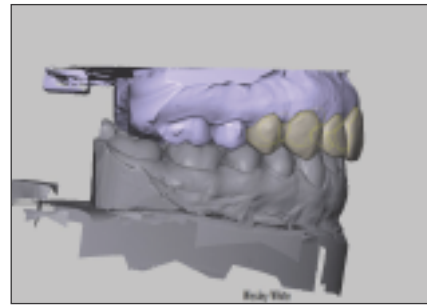


Figure 7. Right lateral view (solid).

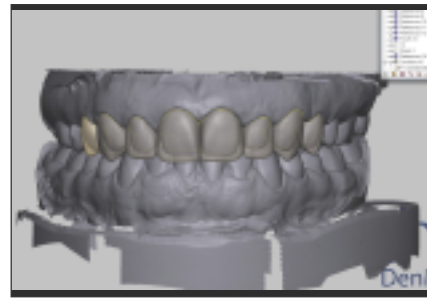


Figure 10. Frontal trans view (transparent).

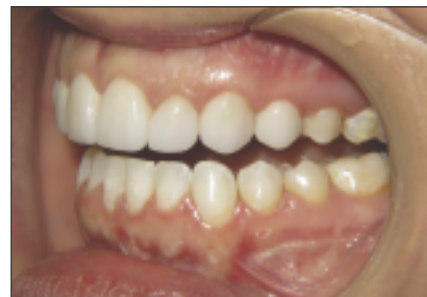

Figure 13. Left lateral view retracted.

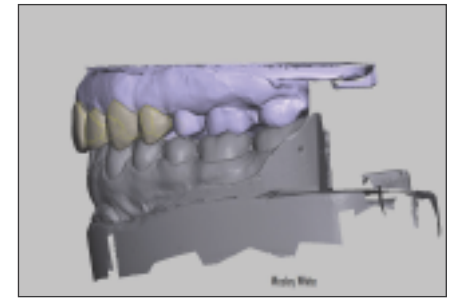


Figure 8. Left lateral view (solid).

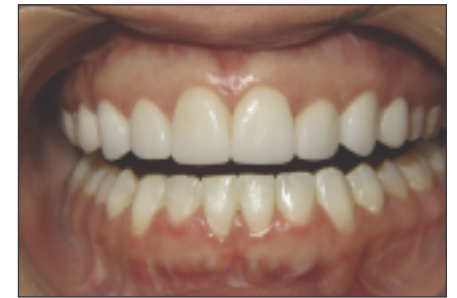

Figure 11. Finished frontal view retracted.

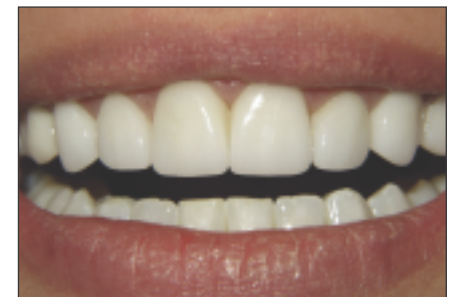

Figure 14. Finished smile nonretracted.

onds facially and lingually was conducted with a 9-mm light-curing tip.

Using a bur and finishing system (designed by DenMat for this restorative system), the remaining resin cement was removed. This was accomplished using the mosquito diamond; 12 and 30 fluted carbides on the facial aspect; and the football-shaped diamond, along with the 12 and 30 fluted carbides, on the L aspect. A finishing kit was used for final bite adjustment, and all contacts were opened (Cerisaw [DenMat]) and smoothed (Cerisander [DenMat]). The final polish was completed with a polishing cup (Dialite [Brasseler USA]) and porcelain laminate polishing paste. Full alginate impressions were also taken for the fabrication of a new maxillary Essix .040 retainer/guard.

As the patient experience is definitive, her statement affords an appropriate conclusion: "My smile looks natural, but more importantly, *it feels natural*. My teeth don't look bulky and my bite feels no different than prior to having Lumineers placed. I am getting compliments left and right on how amazing my smile looks!" (Figures 11 to 14, and After Image).

CLOSING COMMENTS

Minimally invasive Lumineers with a

high level of natural aesthetics were selected for this case, consistent with both expressed patient objectives and clinical assessment. The goal was to deliver an aesthetic smile makeover while preserving the most tooth structure possible.

Digital design was used, as well as pretreatment patient imaging, which supports predictable results. Patient veneers are fabricated as thin as 0.3 mm, therefore requiring minimal reduction of healthy tooth structure. The current generation of leucite-reinforced porcelain allows for very thin (0.3 mm) pressed veneers that are also strong (216 MPa). The manufacturer also provides a variety of fabrication processes from pressed monochromatic to layered polychromatic restorations.

It's important to note that light enamel contouring was needed on this case in order to achieve naturally beautiful, lifelike results. The distinction between no-preparation, minimal-preparation, and traditional full-preparation veneer techniques is often misunderstood and miscommunicated. What makes a veneer restoration minimally invasive? The author suggests that "minimally invasive" applies to any veneer prep technique as long as the least amount of tooth structure is

being removed on that particular case or tooth while still delivering functional, aesthetic results.

It takes a multidisciplinary approach to anterior aesthetics to ensure that all tools at our disposal are being used to preserve natural tooth structure while still achieving the desired aesthetic results. In this particular case, that multidisciplinary approach included orthognathic surgery, detailed treatment planning and risk assessment, soft-tissue recontouring, enamel contouring, and a laboratory partner that delivered an ultra-thin set of aesthetic veneers. ♦

Dr. Harnois practices general and cosmetic dentistry in Hinsdale and Chicago, Ill. He graduated with honors from the University of Illinois at Chicago College of Dentistry in 1982, where he then also served as an assistant clinical professor of Oral Diagnosis from 1983 to 1989. He is the president of the Illinois Chapter of the American Academy of Facial Esthetics (AAFE) and a member of the American Academy of Cosmetic Dentistry, the World Clinical Laser Institute, the American Dental Association, the Illinois State Dental Society, and the Chicago Dental Society. He is also a Fellow and faculty member of the AAFE. Dr. Harnois is a nationally recognized speaker who lectures for NuCalm; the AAFE on Botox and dermal fillers; and for DenMat on Lumineers, Snap-On Smile, and oral cancer detection. He can be reached at pthdental@ameritech.net.

Disclosure: Dr. Harnois is a nonpaid consultant for DenMat Holdings. He received no compensation for writing this article.